

IPS Empress® Esthetic

Special Edition



MATT ROBERTS

Matt Roberts





The IPS Empress® pressable ceramic material has been used by ceramists to provide patients with very esthetic indirect restorations for more than 17 years. With over 25 million restorations placed worldwide, it's easy to see why IPS Empress materials have become the standard for indirect inlay, onlay, full-contour crown, and veneer restorations. IPS Empress was originally designed with surface color and stain, but it was lacking in the area of incisal detail. Lee Culp and Jürgen Seger started doing cutbacks and mixing correction powders that were designed for layering different colors on ingots. I started doing that shortly after Lee in the early 90's and we used that successfully until last year, when Ivoclar Vivadent came out with incisal layering porcelains and ingots that worked well together. This is the history behind the development of IPS Empress Esthetic. The system's newest components – the IPS Empress Esthetic ingot, IPS Empress Esthetic Veneering Materials, and IPS Empress Esthetic Wash Pastes – allow you to optimize the materials performance and esthetics by refining the optical, chameleon, and functional aspects of the restorations.

The biggest advantage to using the IPS Empress Esthetic system is that you can quickly and accurately transfer the entire envelope of function and shape of the restoration to your final wax-up from successful provisionals via an injection process. This not only lends accuracy to the final restoration in terms of shape and position, it also saves substantial waxing

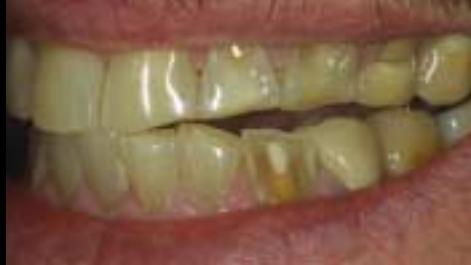time. You can do this in about 90 seconds with very predictable results, versus the 3 hours it used to take. Historically, the waxing process for restorations like these consisted of a technician dipping a hot instrument into cold wax and touching it to a stone model to build up little piles of wax until the whole wax-up was created. Now, using the injection process to capture shape and other details, the temporaries become the "mold" for the finals.

Another advantage realized with IPS Empress Esthetic is having only to build up the incisal edge if you chose to use the cutback technique. You used to have to layer all the way from the cervical margin to the incisal edge to achieve characterizations. This new ingot material accurately replicates enamel over dentin in the gingival half, and you can achieve a little more translucency in the incisal half by doing the type of layering described in this Special Edition.

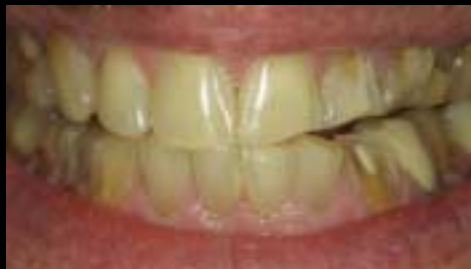Combining the improved homogeneity, natural translucency, and fluorescence of the ingots with the 14 new veneer layering materials allows you to create internal characterizations, recreate mamelons, and truly customize natural-looking pressed ceramic veneers or anterior crowns. We now use it for approximately 80% of the restorations we do in the laboratory. Because these new opalescent incisors and shading materials are easy to handle and fire, incorporating this technique into your current regimen is simple and will yield the esthetic results you, the dentist, and patients will really be wowed by.



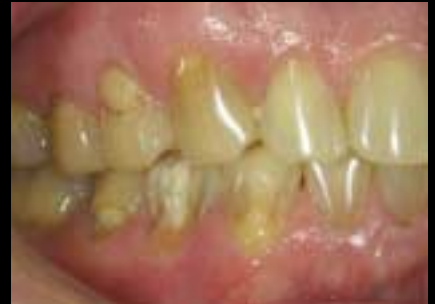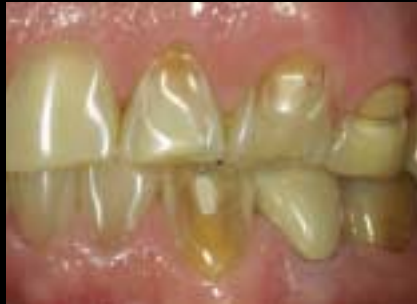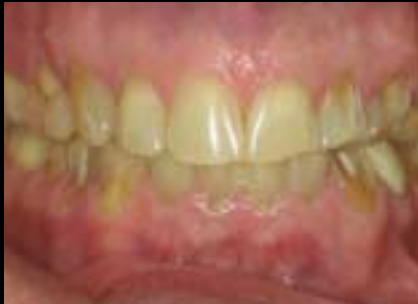Full face preoperative photo.



Preop close-up of occlusion.



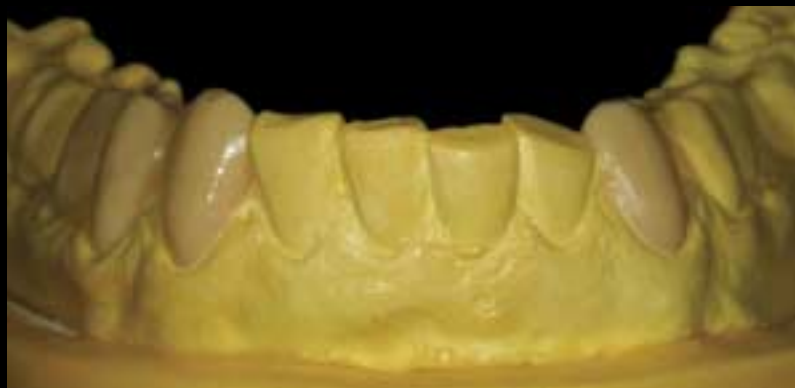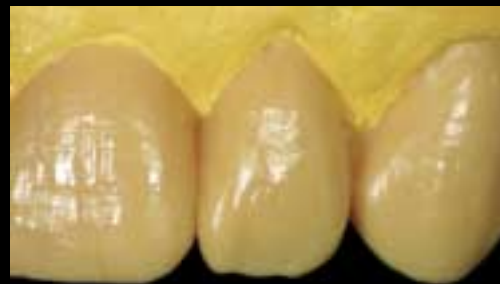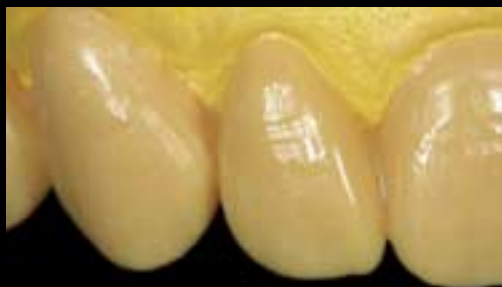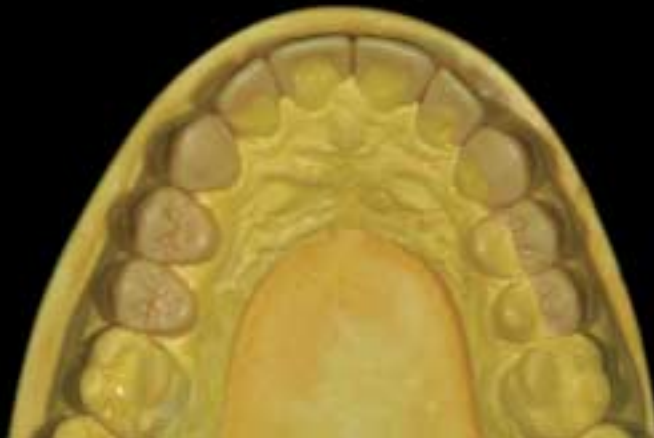
Retracted. Preoperative condition displays wear and erosion.



Lateral views demonstrate wear and erosion as well.

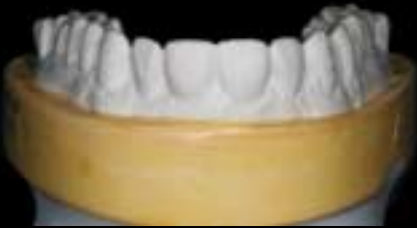Wax-Up

A Diagnostic wax-up is accomplished, taking into account the patients esthetic and occlusal requirements. An impression of the completed wax-up will be used intra-orally to fabricate the temporary restorations.





After the provisional restorations are approved, they are cemented with temporary cement and a photograph is taken. An impression is made to capture the shape and other details of the temporaries. The impression of the temporaries is placed on the stone model of the prepared teeth. A small hole is made in the incisal edge and liquid wax is injected into the spaces around the preparations to reproduce the shape of the temporaries on the stone model. Then the wax-up is refined, and any shaping details are designed as necessary for optimal function and esthetics. The wax-ups are then invested and pressed using standard techniques.



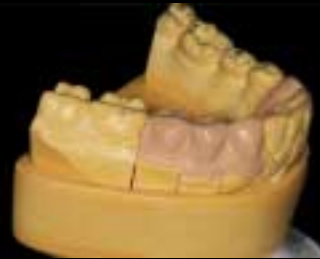White temporary model.



Silicone matrix, using SilTech® Putty, being taken of the white temporary model.

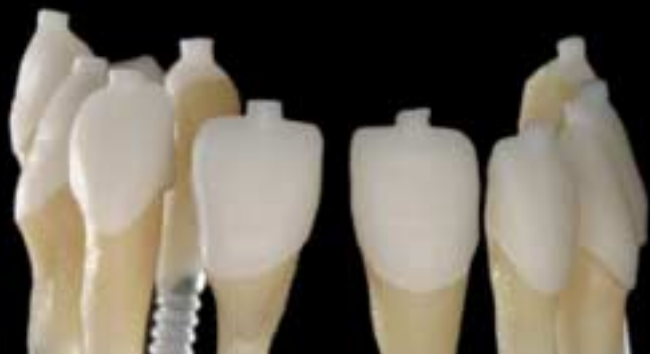

Injection tool going into the matrix.

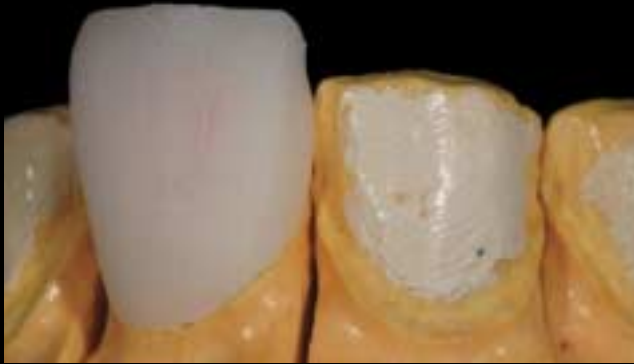

Preliminary wax-up with the sprue still attached.

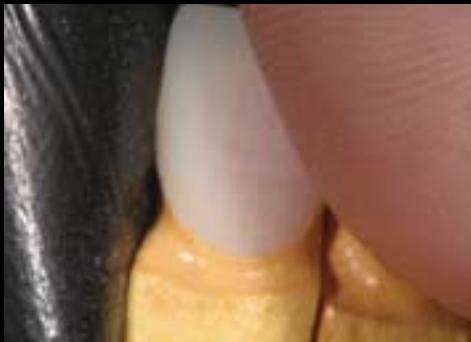IPS Empress Esthetic E TCO restorations mounted on IPS Natural Die Material.



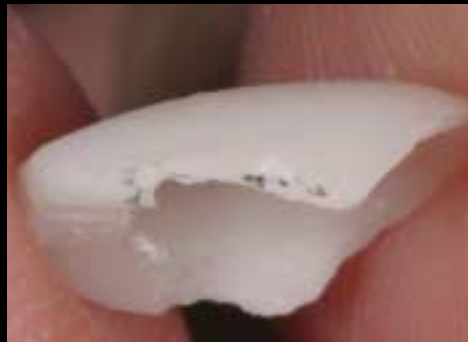Contouring



Fit the restorations from the Stumpf dies back on the stone model. When the midline is not broken it is hard to seal margins in wax without compromising the contact. Die spacer has been added to the model to create space for luting materials when the restorations are seated.



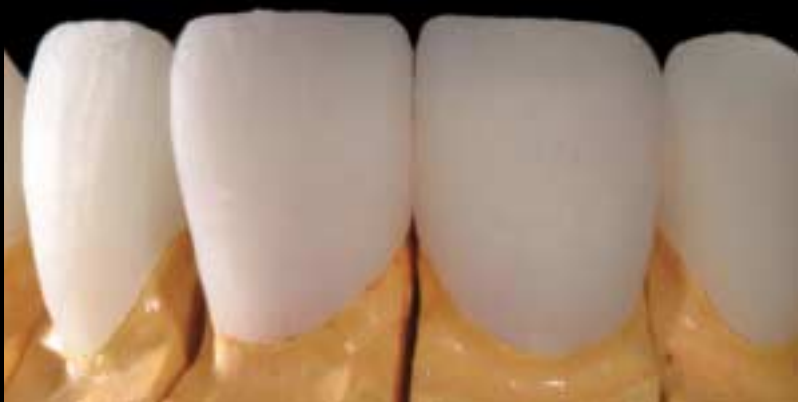Accufilm is used to detect interferences.



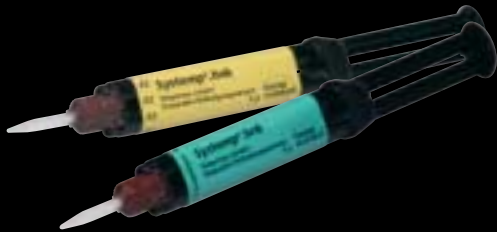Marks from Accufilm indicate interferences to seating.



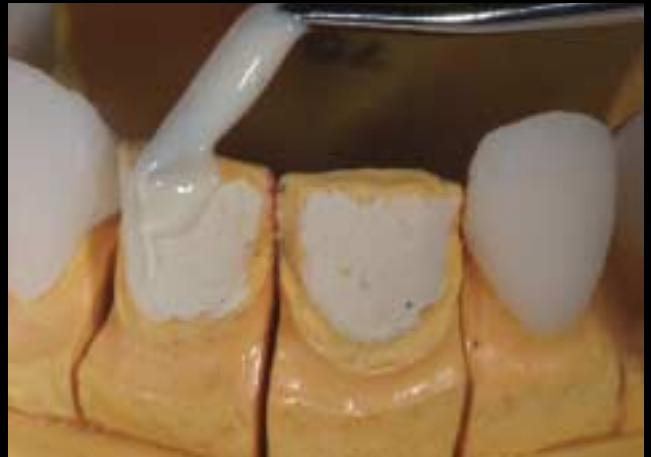It is important to use a straight-sided diamond to adjust the interferences and reestablish contacts without creating black triangles.



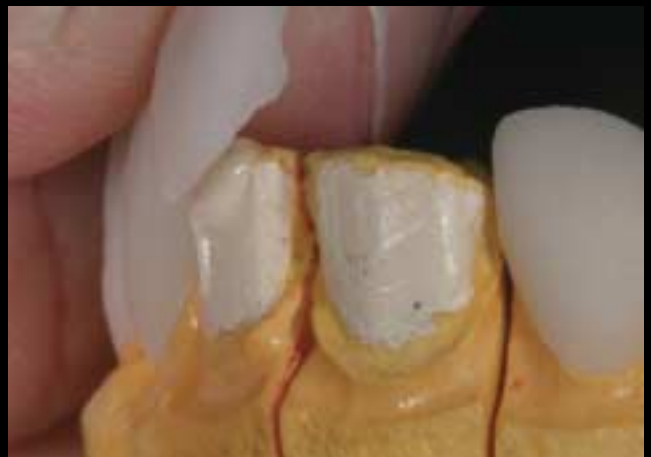Contact is reestablished and restorations are fitted back onto the model.



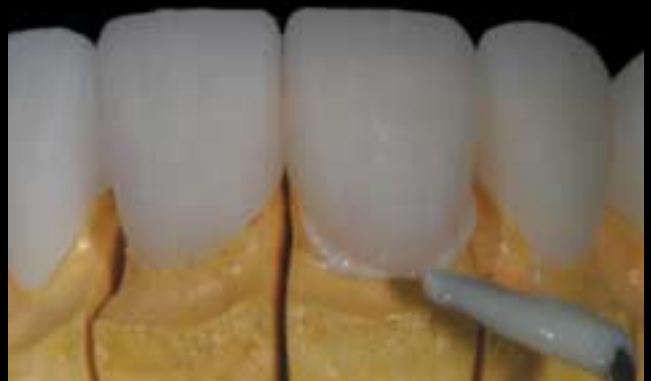Systemp.®link temporary cement is used to hold restorations on the model. It is important to use a little of the separator from the IPS Natural Die Material Kit on the ceramic so it doesn't bond too tenaciously to the die.



Apply a small amount of cement to the die, ...



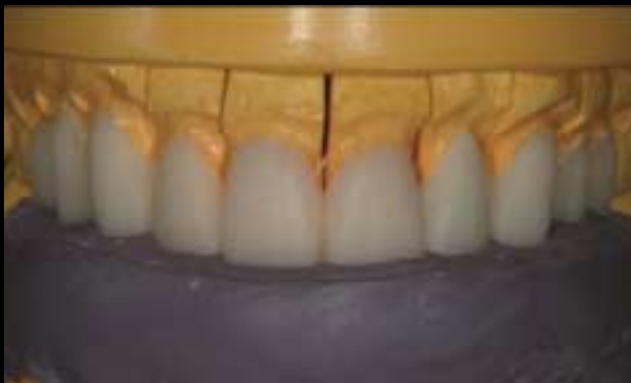... push the veneer down onto the die, ...



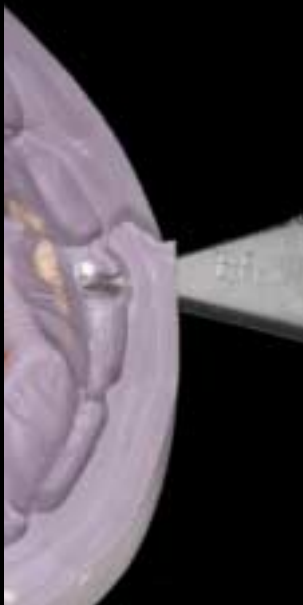
... and wipe off any excess cement as it extrudes.



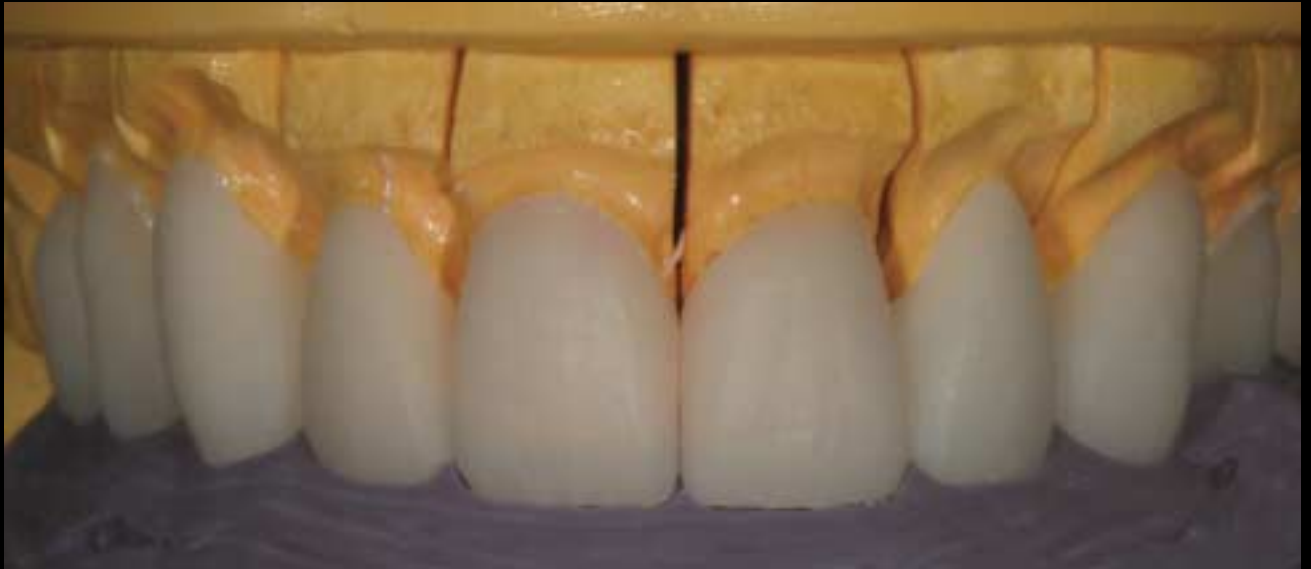After Systemp.link application, the veneers are light cured to hold restorations on the dies while they are being contoured.



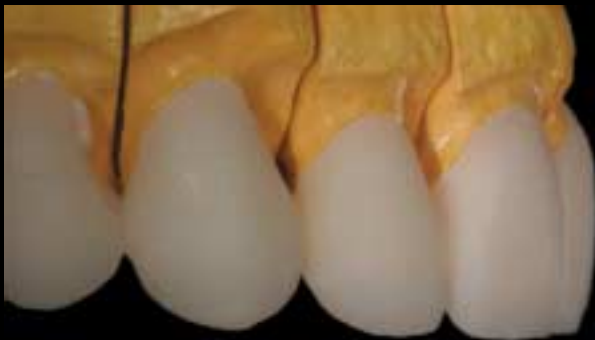An incisal matrix is used to record the incisal edge position against the lower arch model.



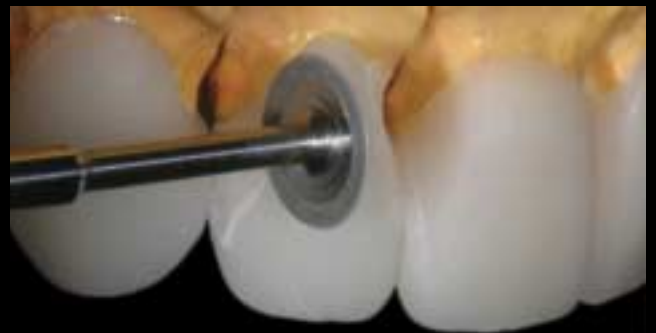It is important to trim the matrix so that the facial incisal edges of the anterior restorations are right at the edge of the matrix. Doing this will make it easy to see any change in the incisal length.



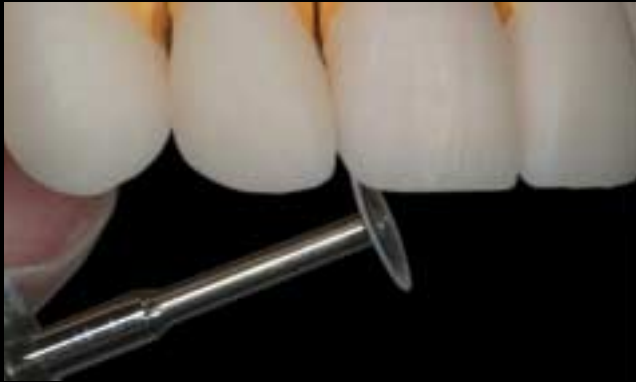After trimming the matrix, place the restorations back into the matrix to verify they fit accurately. They should be fully seated into the matrix.



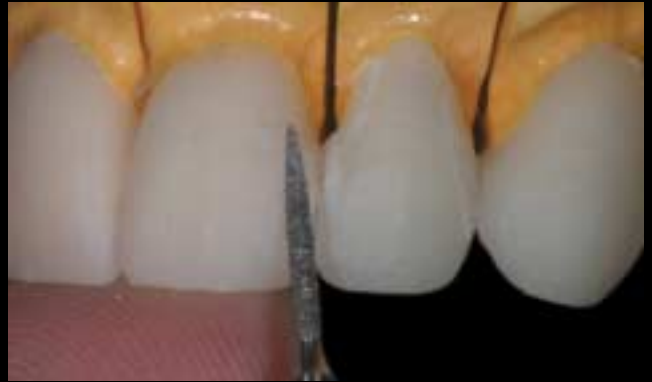The result of detailed waxing is reduced finishing time; it also will reduce the necessity of grinding the porcelain. Here, you can see the surface lobe formation detail that was picked up from the waxing, before any grinding was done.



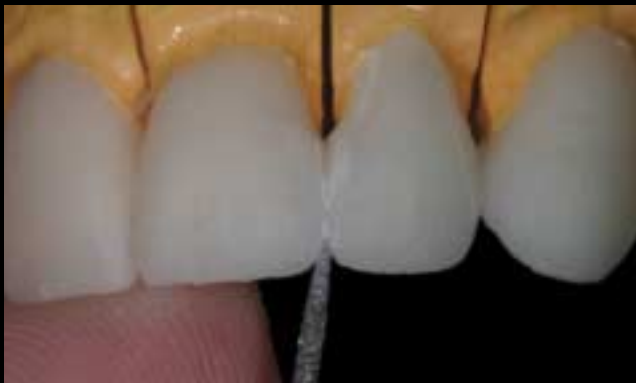Embrasure areas are opened slightly to allow illumination of the papilla and prevent a bulky, overcontoured look.



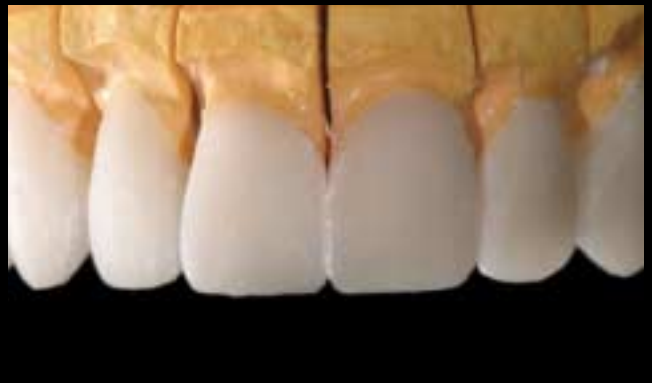Incisal embrasures are refined.



A smaller diamond is used to soften any transition lines left by the disk.

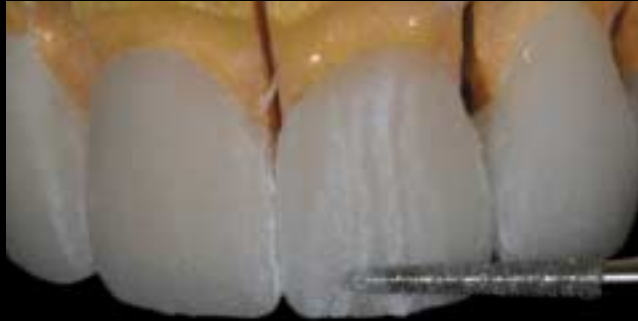

Incisal embrasures can also be refined using a small tapered diamond.

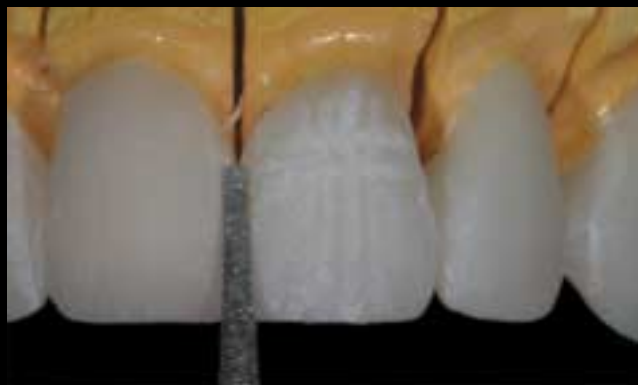

Initial adjustments to the silhouette and reflective shape are refined before starting on the surface morphology.

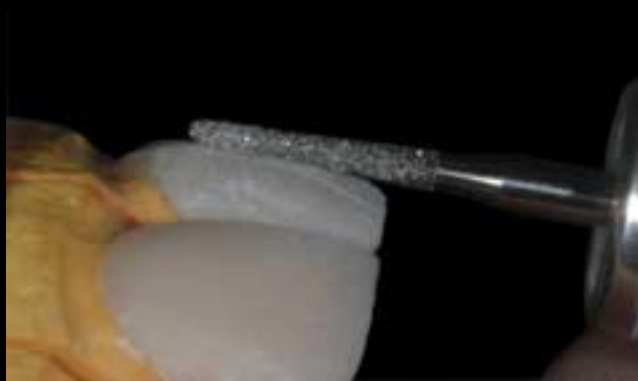Surface Texture



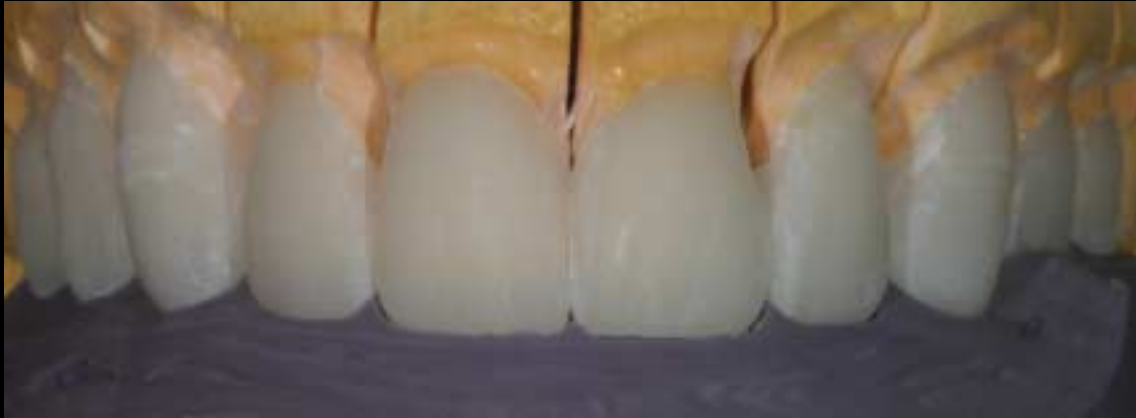The mesial half of the middle lobe is formed.



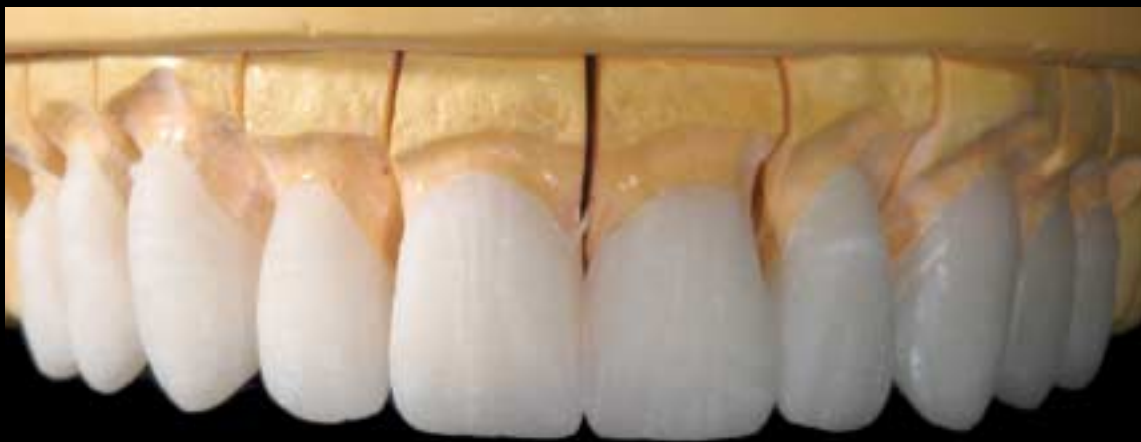The horizontal structure at the gingival half is established.



Creating reflective facets.



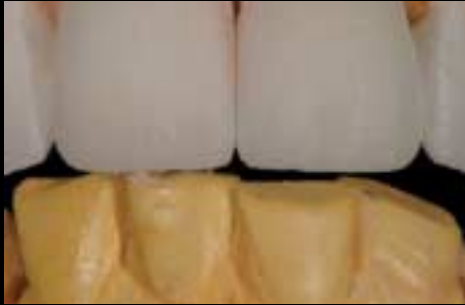The matrix is re-checked after contouring, and before cutback.



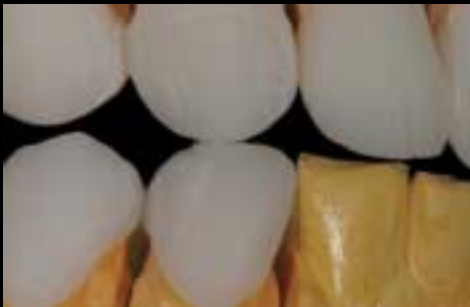Final contours complete.



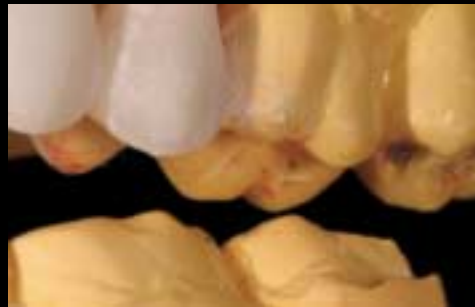Function Evaluating Envelope of Function



The functional evaluation detected the need for further restorative treatment to the lower anterior teeth to distribute occlusal forces. The dentist was informed that the end-to-end protrusive position demonstrated that the forces of occlusion would not be evenly spread across the lower teeth. This was corrected with direct composite restorations on the lower central and lateral teeth in this case. This diagnosis could also have been treated with additional porcelain veneers.



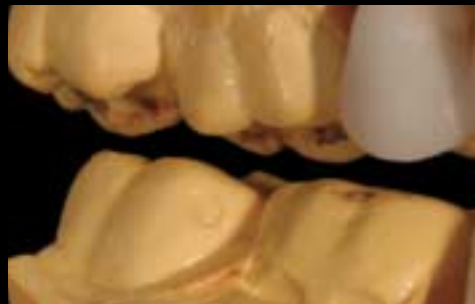Canine disclusion is evaluated.



Note that the canine disclusion is clearing any balancing interferences.



Evaluating canine guidance on the other side.



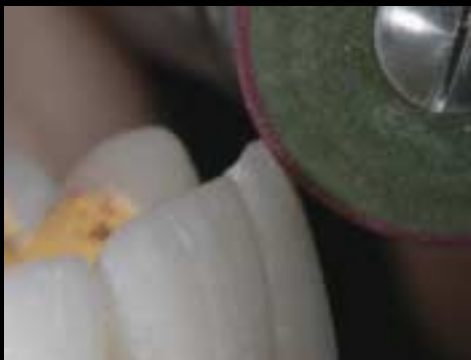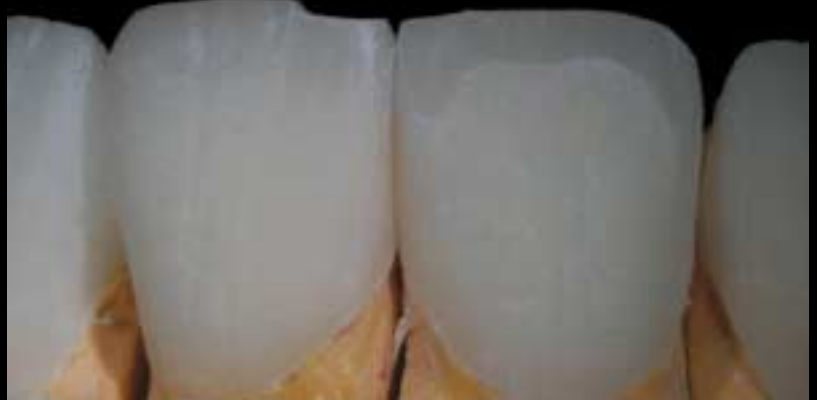Balancing side.

Effects

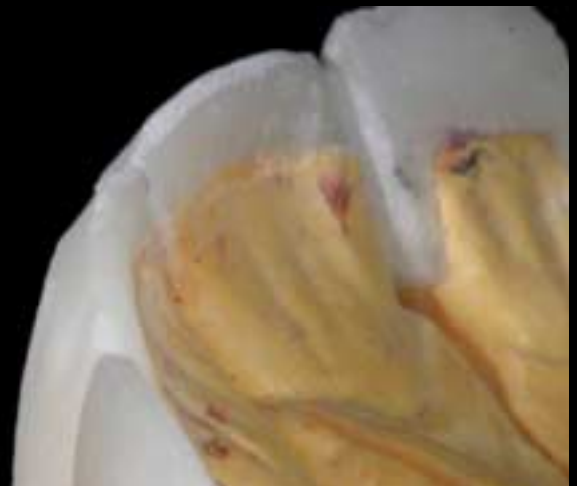Cutback for Incisal Effects

Because this is a pressed ceramic material, the whole tooth is the same color and value. Natural teeth are different colors and translucencies at the margins and around the incisal edge. Choose an ingot that is an appropriate base color for the gingival half of the tooth that won't need to be layered over to look natural. The base ingot will also filter the underlying tooth color and provide the right shade, texture, luster, and translucency to the surface.

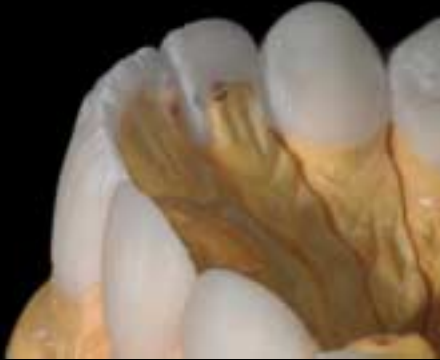In the incisal area, the base material is too dense to replicate the internal structure we see in natural teeth, so we cut away the area we want to be more translucent in a very systematic manner. First, shorten the teeth by the amount of translucency you want, and then feather it from the facial and the lingual to create a very sharp-edged cutback. Note the vertical cutback on tooth No. 11 and the whole facial cutback prior to dental lobing on tooth No. 21. You can see how much it has been shortened in the process of cutting back.



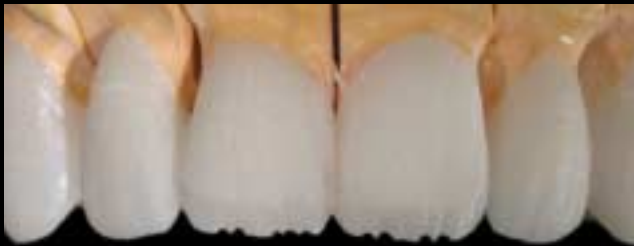A diamond-impregnated wheel is used to cut back the incisal edge at an angle.



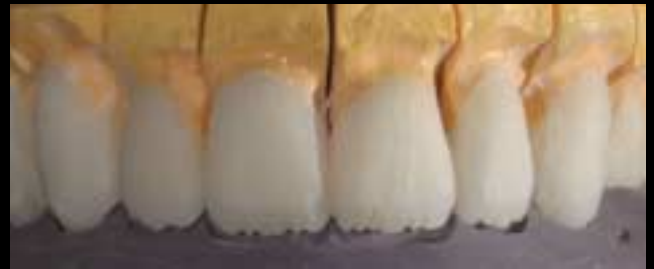The cutback should form a rounded edge to ensure blending into the more translucent incisal area. The base material should fade out to create a zone of transition between the two opacities.



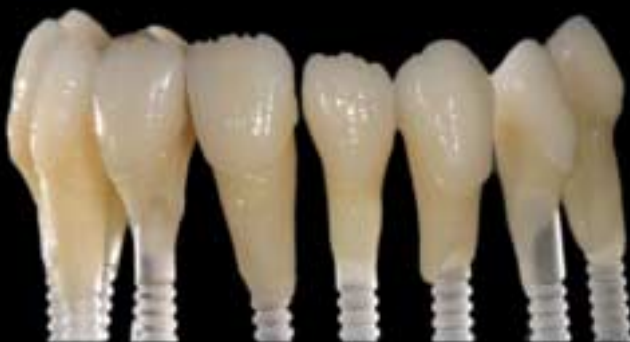Note the dentin lobing created during the cutback phase. Typically, the central incisors have three dentin lobes that are like opaque fingers running through the translucent incisal edge. The lobes you cut into the incisal edge should look like a serrated knife blade; however, be careful not to create sharp lines of demarcation.



Dentin lobe formations are reflected in incisal translucency patterns; the cutback should represent dentin lobe shapes.

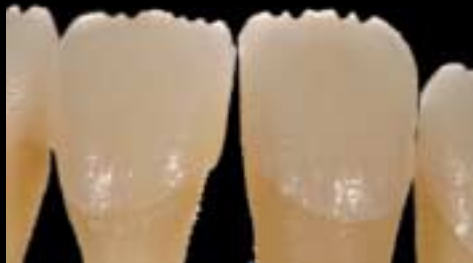

The matrix is used to evaluate the amount of incisal translucency created. Evaluate the overall shape of the translucency pattern and establish how much of a translucency band you're going to have on the various teeth. At this point, you can adjust the amount of reduction. Using the matrix keeps you oriented to where the shape should be. The matrix can be made from the temporary model, and then checked again repeatedly on the pressed-ceramic model until the restorations are finished.

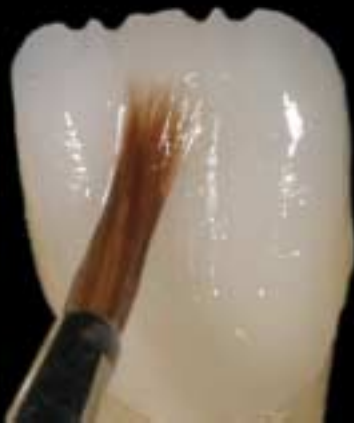

Much of the color seen in IPS Empress Esthetic restorations comes from the underlying dentin layer, so it is important to use composite Stumpf dies, which replicate the color of the dentin when staining these restorations. After the cutbacks are finished put the restorations on the Stumpf dies to verify the color of the underlying material, what the dentist/patient's desired color is, and start applying stains to characterize the teeth and make them look more natural. On the cutback, I use the wash pastes. Paint the pastes on the teeth and the interface that has been cut back in the incisal area to create some internal effects (which will later be layered over) in the incisal third.

Layering for Incisal Effect



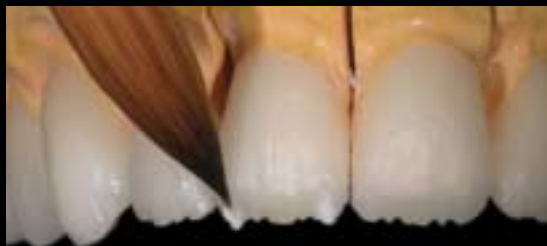Reverse illumination shows the translucency achieved just by thinning the incisal cutback. This helps prevent a harsh translucency demarcation line in the incisal third.



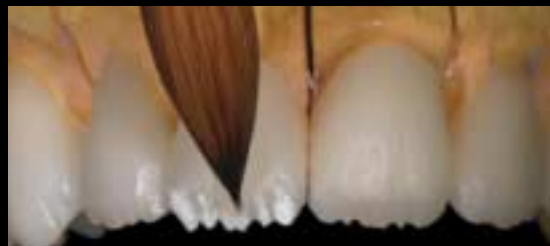Wash pastes are used to create characterization effects in the incisal third and to establish a bond with layering materials. After the colored pastes are fired, clear neutral wash paste is applied to the remaining incisal third.



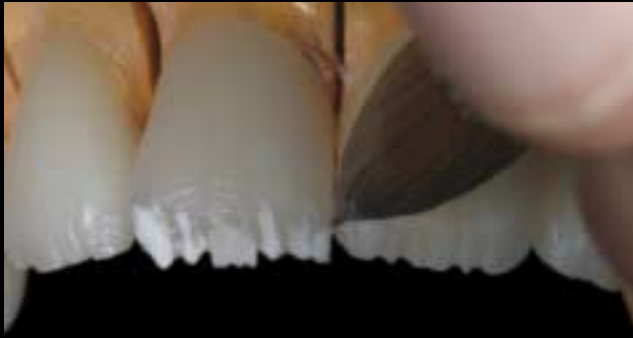For this case I used IPS Empress Esthetic Incisal powders white, yellow, blue and Opal Incisal HT (High Translucent).



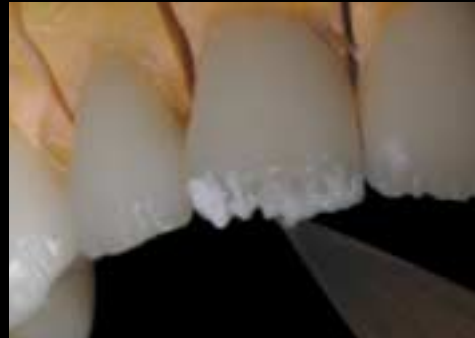This series demonstrates how the incisal layering is accomplished. Here, incisal white powder is used on the mesial, distal and as an accent in several places in between.



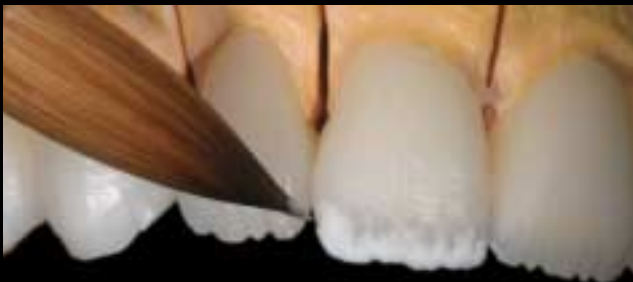Small amounts of yellow also are used, primarily in the middle of the incisal.



Some of the blue is placed just outside of the white to create a little band of translucency around the mesial and distal corners.

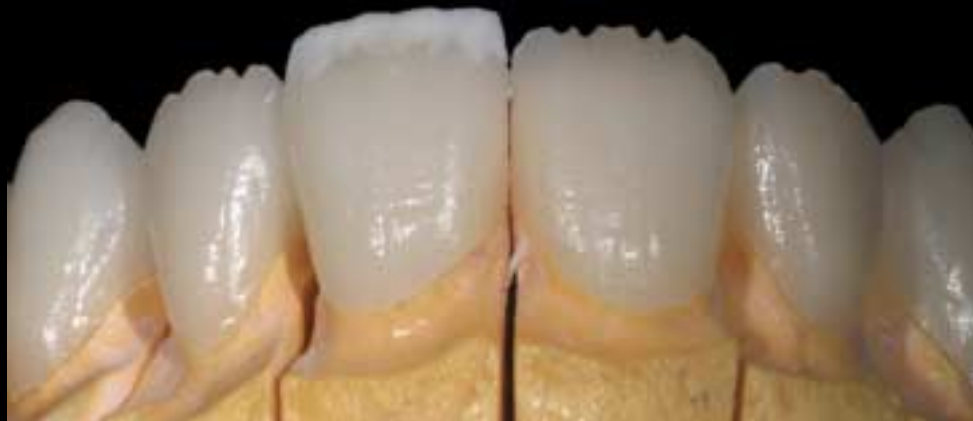

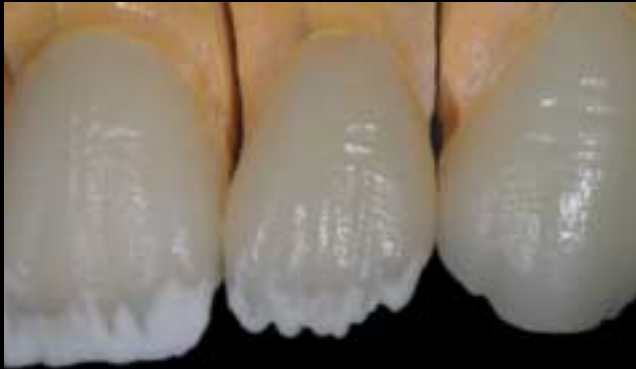Fill in with Opal Incisal HT (High Translucent) to silhouette the structure shapes we just created. This achieves a thin band of translucency.



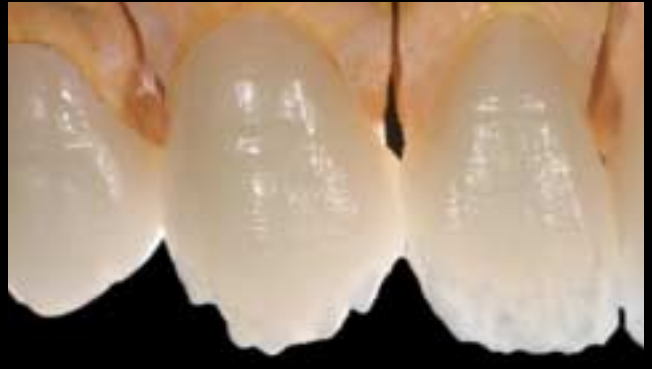The silhouette of the tooth is filled out, but note that the buildup is very thin facial-lingually and is still undercontoured. This will serve as a palette for stains and mamelon pastes. This also provides a two-dimensional silhouette of how the tooth will look from the facial incisal-edge position.

The completed silhouette on the central incisor.

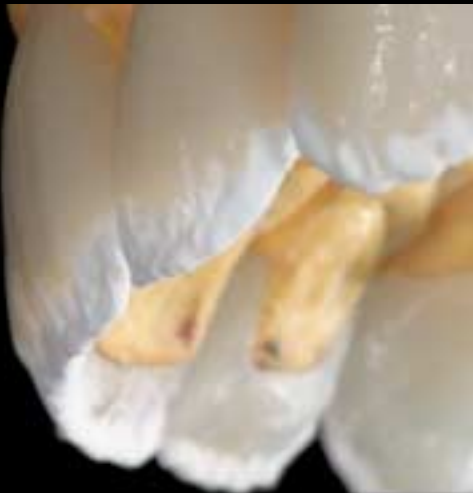



Note: the dentin lobe patterns in laterals differs from those in centrals.

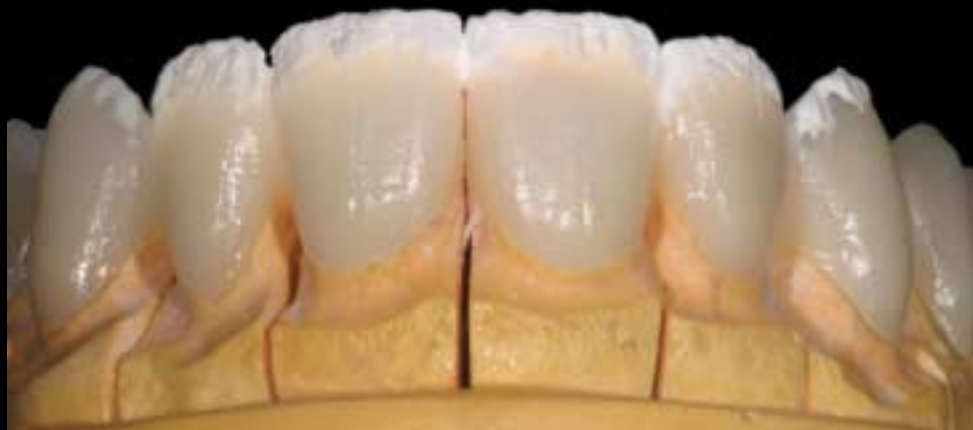

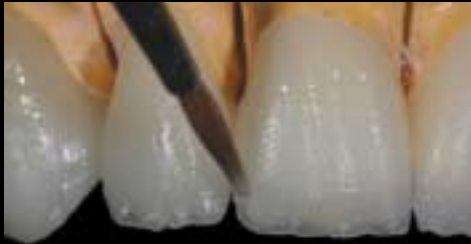Cuspids also display their own unique translucency patterns.



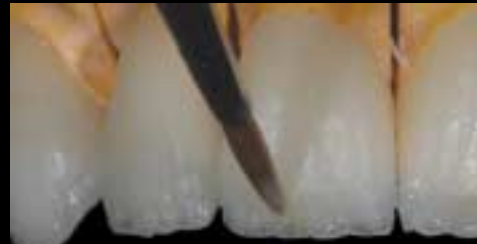The effect buildup is kept very, very thin, just like the cutback.

Backlighting helps you see where the procelain is from a facial view.

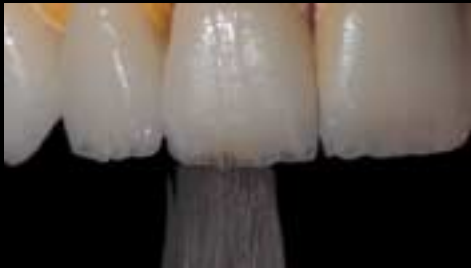



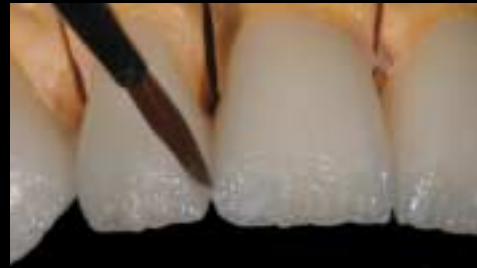Next, the mamelon wash pastes are added. High Value paste is used on the mesial and distal, and a few streaks are placed in the middle of the tooth. This is starting to give the incisal edge a little more pizzazz.



Here, we're adding Mamelon Light-Salmon throughout the incisal, and Yellow-Orange or Reddish-Orange to create accents in the middle.



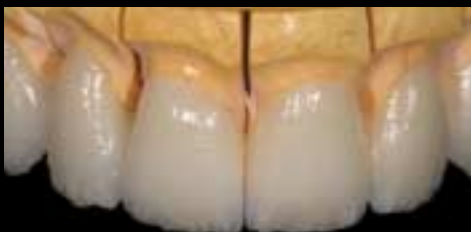A splayed porcelain brush is used to feather the effects and to blend them in lightly at the incisal edge.



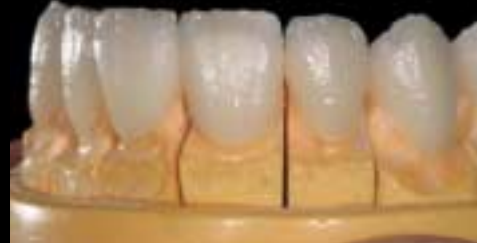A low-value blue is used on the mesial and distal to provide interproximal translucency.



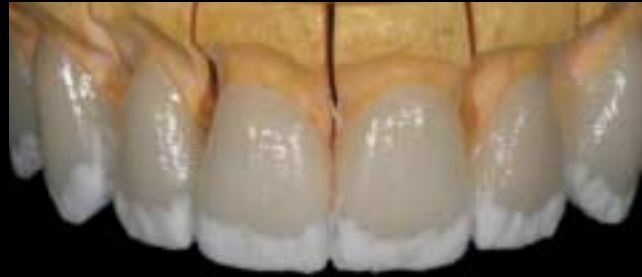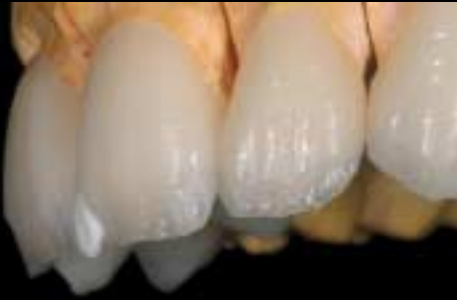The fired result of all these effects is a very dynamic, polychromatic color gradation in the incisal third of the teeth.



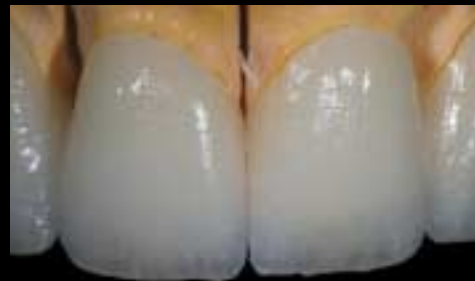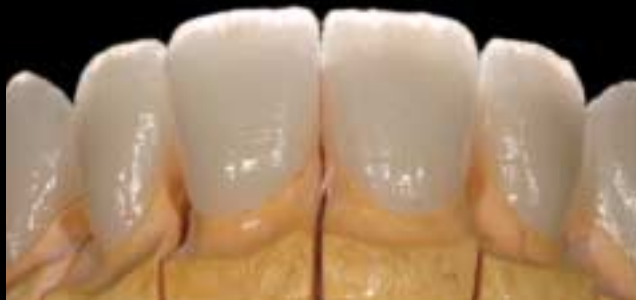If necessary, incisal effects can be modified by adding more porcelain or grinding away excess before filling out to final contour.



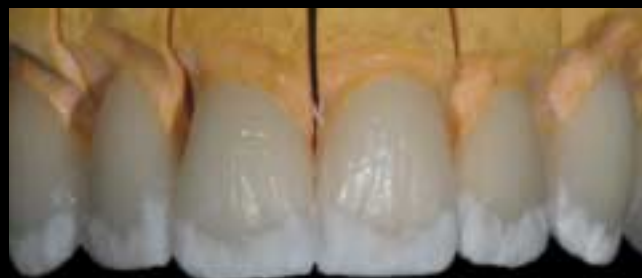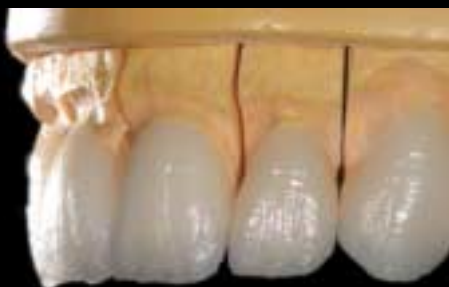Fired result of the incisal palate and the mamelon effects.



Opal Incisal HT (High Translucent) is then used to complete the desired contour and encapsulate all the previous effects.

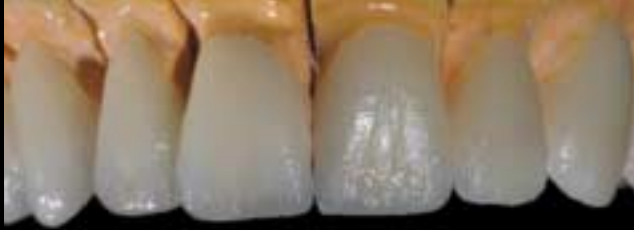

After a layer of High Translucency is fired over the effects palette, halos will form naturally in this material or can be enhanced with an opacified incisal edge material.

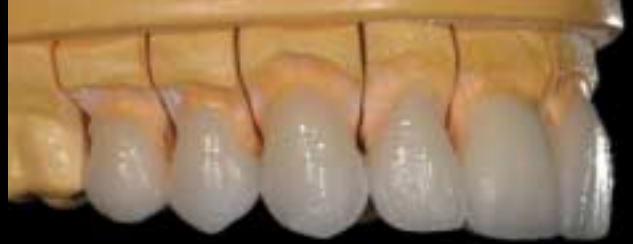

The gingival half of the restorations are complete, but the incisal third must be contoured to blend with gingival lobe patterns.

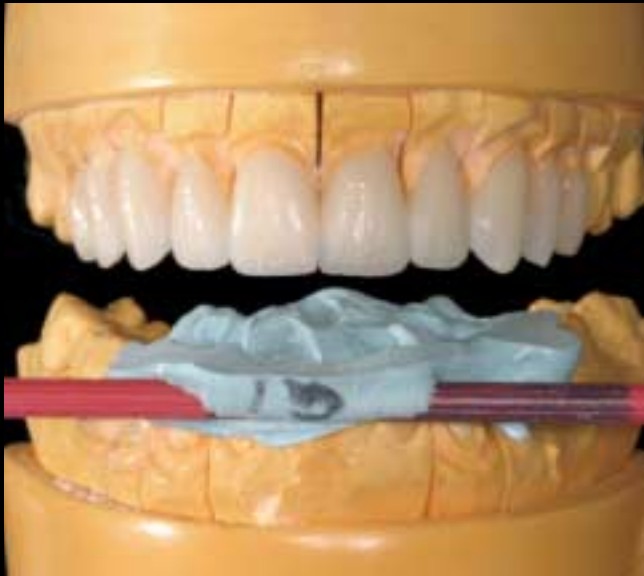Second incisal correction buildup to fill any deficient areas.



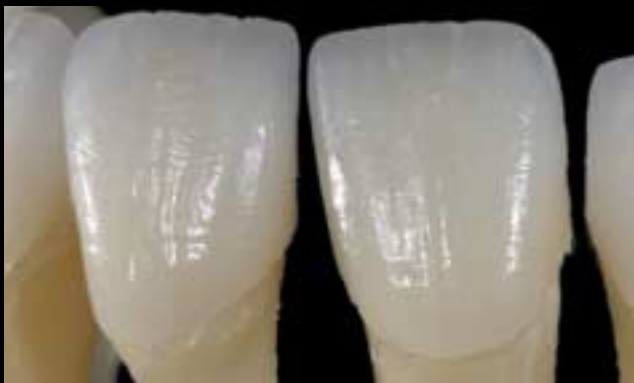Incisal after firing, but before grinding.



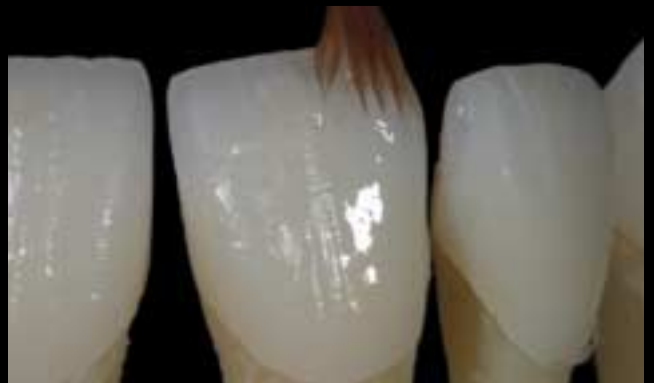Incisal shape is reestablished by grinding without adversely affecting the finished gingival areas.



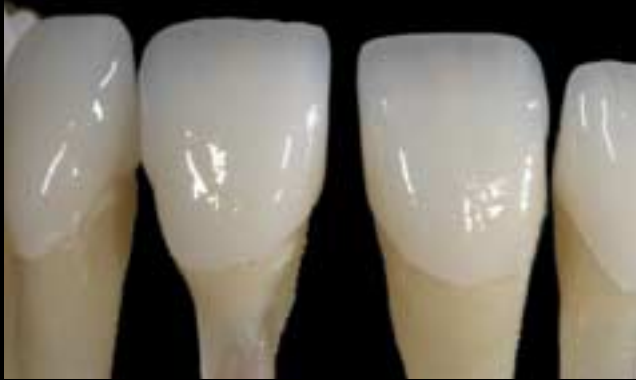The midline and incisal plane are evaluated with a horizontal plane tool and stick-bite. The stick was set up to be level with the patient's eyes. Our midline must be perpendicular to that and the incisal edge should follow that line.



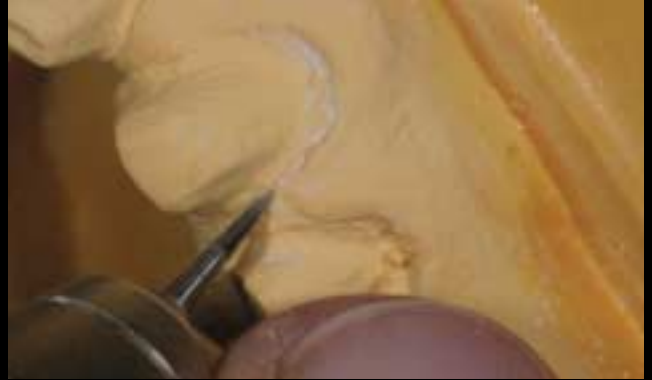
Final contour before glazing.



IPS Empress Universal Glaze is applied.



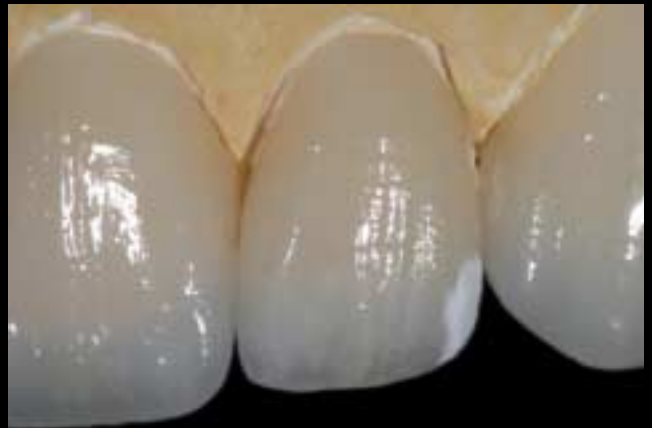Incisal translucency patterns are soft, feathery, and natural in appearance. After everything is glazed, the next step in creating high quality restorations is to fit the veneers to a solid model with the tissue/gingival architecture still intact. I spend a lot of time fitting and adjusting the restorations to a solid stone model that has not been sawed and still has the soft tissue in place to ensure that the final restorations tuck right in to the patient's soft tissue, look natural, and will not cause any clinical problems.



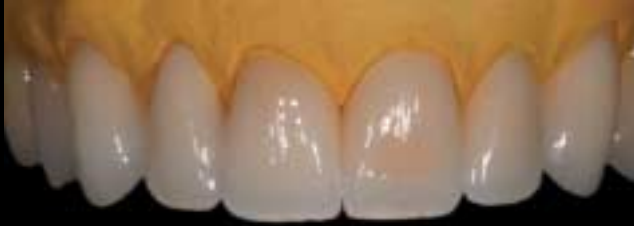The solid model is trimmed with a sharpened carbide bur in a high-speed handpiece to open up the sulcus without damaging the tissue detail.



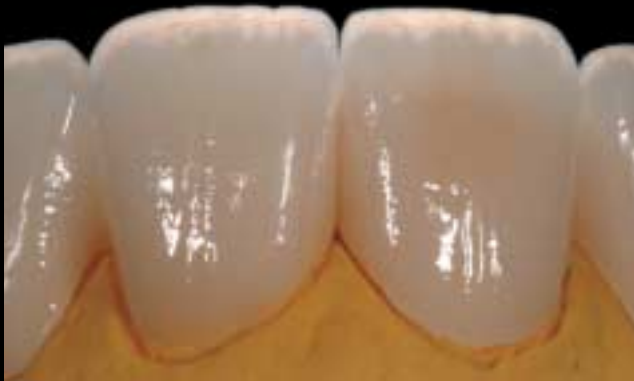The restorations are set on the stone model and proximal contacts are adjusted with Accufilm.



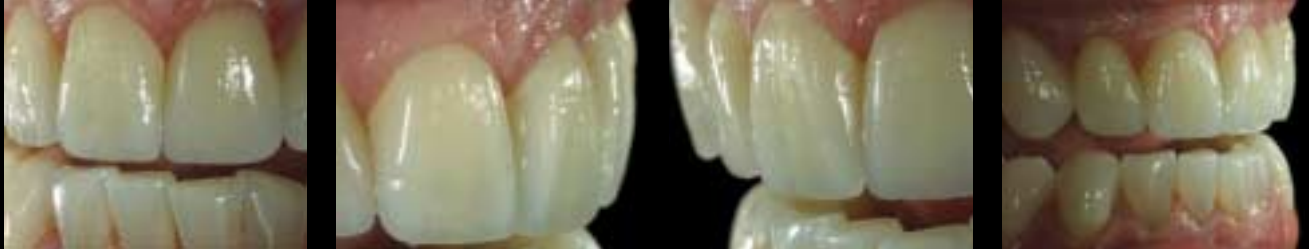Small corrections are made to control the shape of the incisal embrasures, improve contours, fill in any black triangles gingivally, etc, and fired.



Contacts should extend from the incisal embrasure to the tip of the papilla, thus preventing any black triangles above tissue level.



Reverse illumination captures the opalescence of the incisal materials.

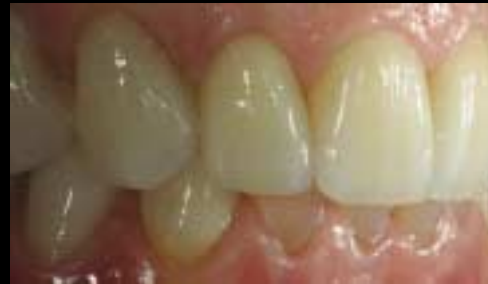
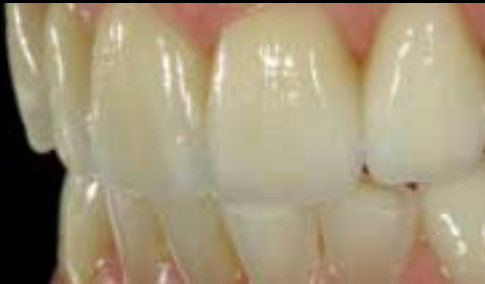
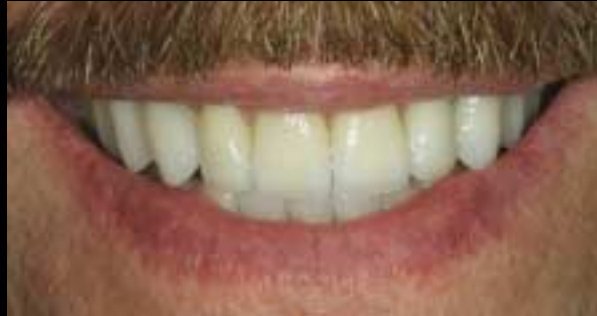Clinical photos taken the day of placement. The patient had undergone tooth whitening and the restorations are a perfect match.

An explosion of color demonstrated with special photography.



Two Months
**Restorations Two Months
After Placement**





Press for Fit...
Layer for Beauty!

